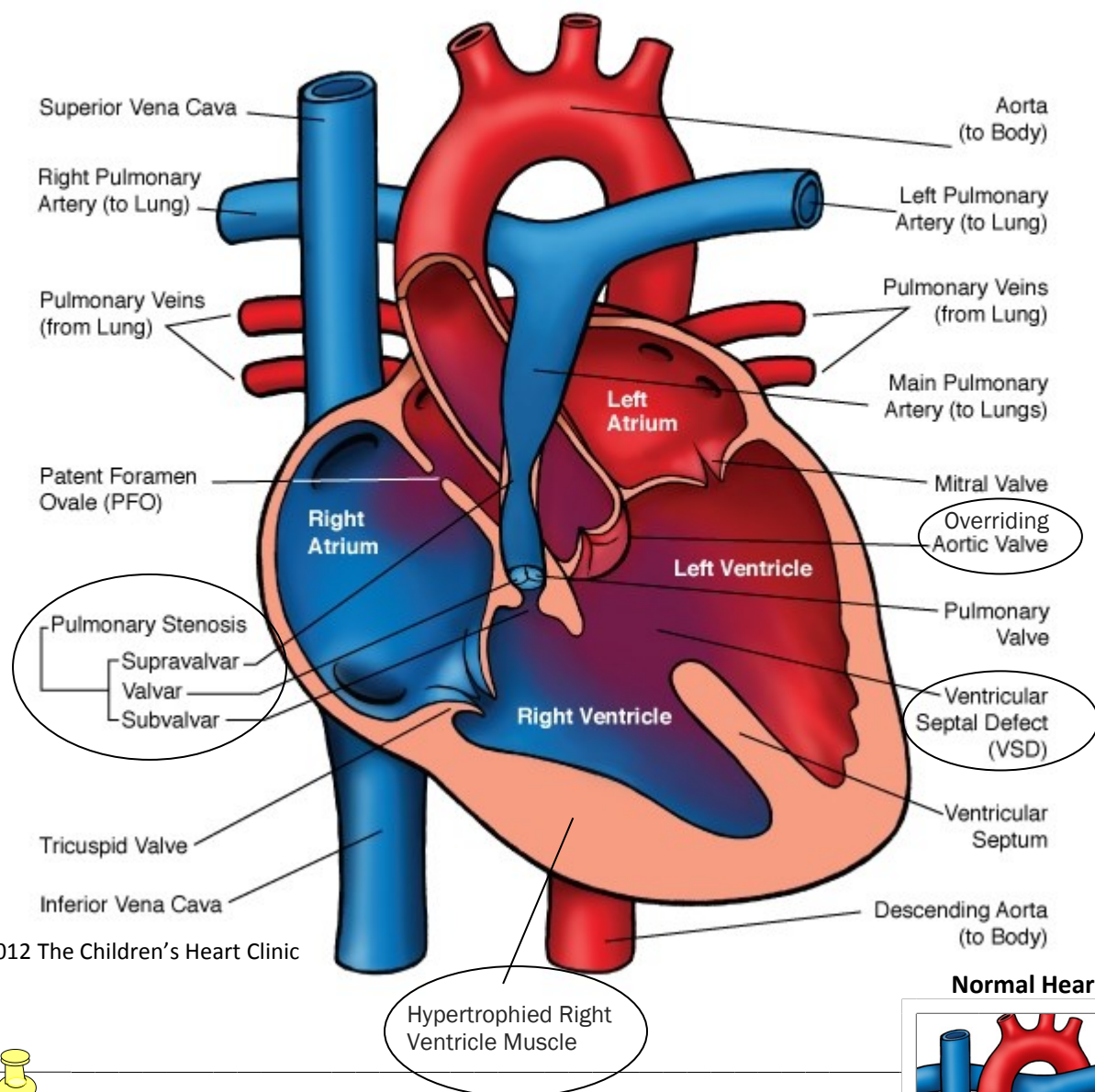
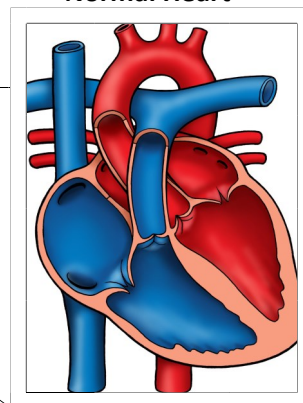


Tetralogy of Fallot



© 2012 The Children's Heart Clinic

Normal Heart



NOTES:

Children's Heart Clinic, P.A., 2530 Chicago Avenue S, Ste 500, Minneapolis, MN 55404

West Metro: 612-813-8800 * East Metro: 651-220-8800 * Toll Free: 1-800-938-0301 * Fax: 612-813-8825

Children's Minnesota, 2525 Chicago Avenue S, Minneapolis, MN 55404

West Metro: 612-813-6000 * East Metro: 651-220-6000

Tetralogy of Fallot (TOF)

In the normal heart, there are two atria and two ventricles. Blood comes back from the body from the superior vena cava (SVC) and inferior vena cava (IVC) to the right atrium through the tricuspid valve to the right ventricle. The ventricle contracts and blood is pumped through the pulmonary valve to the pulmonary arteries out to the lungs where the blood is oxygenated. Blood returns from the lungs by the pulmonary veins to the left atrium. It then travels from the left atrium through the mitral valve to the left ventricle. The left ventricle contracts, sending blood through the aortic valve through the aorta and out to the body.

The classic description of Tetralogy of Fallot (TOF) includes four cardiac abnormalities: an overriding aorta, right ventricular hypertrophy (RVH), large perimembranous ventricular septal defect (VSD), and right ventricular outflow tract obstruction (RVOTO). By current description, only RVOTO and a large VSD are required for diagnosis of TOF. RVH is due to the large VSD and RVOTO and the overriding aorta may vary. RVOTO is most often in the form of infundibular stenosis (45%). A combination of infundibular stenosis and pulmonary valve level stenosis occurs 30% of the time. In the most severe cases of TOF, pulmonary atresia occurs (10%). Stenosis (narrowing) of the branch pulmonary arteries is common and a right aortic arch may be present (25%). Complete atrioventricular septal defect occurs in 2% of children with TOF, most commonly in those with Down syndrome. TOF occurs in 10-14% of children with congenital heart defects and is the most common cyanotic defect.

Physical Exam/Symptoms:

- Heart murmur is present at birth. A grade III-IV systolic ejection murmur is heard best over the left middle to upper sternal border. The more severe the RVOTO, the softer and shorter the murmur.
- A systolic thrill may be present over the left middle sternal border (50%).
- Cyanosis at birth or in early infancy is common. Severe cyanosis is present for neonates with pulmonary atresia.
- For children who are desaturated, difficulty breathing with exertion or hypoxic spells (“tet” spells) may develop.
- Acyanotic (“pink”) TOF occurs in children with a large ventricular left to right shunt. These infants may be asymptomatic or may develop signs of congestive heart failure (CHF).

Diagnostics:

- Chest X-ray: Heart size is usually normal. Pulmonary vascular markings are often decreased; absent in infants with pulmonary atresia. The heart often appears “boot-shaped” due to a concave main pulmonary artery segment and upturned apex.
- EKG: RVH is usually present. Right axis deviation may be present in infants with cyanotic TOF, with a normal QRS axis in infants with acyanotic TOF.
- Echocardiogram: Diagnostic of TOF and severity.

Medical Management/Treatment:

- Prevention of bacterial endocarditis and good dental hygiene are important.
- Recognition and treatment of hypoxic spells by helping the infant/child into a squatting position, administration of oxygen, and sedation when needed. These spells resolve following surgical intervention.

Tetralogy of Fallot (TOF)

- Timing and choice of surgical interventions are based on symptomatology, specific physiology, and the size of the infant/child (see [TOF repair](#)). Your child's cardiologist will discuss this with you.
- Life-long cardiology follow up every 6-12 months is recommended.

Long-Term Outcomes:

- Late arrhythmias such as ventricular tachycardia may occur.
- For children with uncomplicated TOF, the mortality rate is 2-3% in the first 2 years of life.
- Growth and developmental for children with TOF vary and are impacted by the presence of additional congenital heart anomalies, associated syndromes and other co-morbidities.