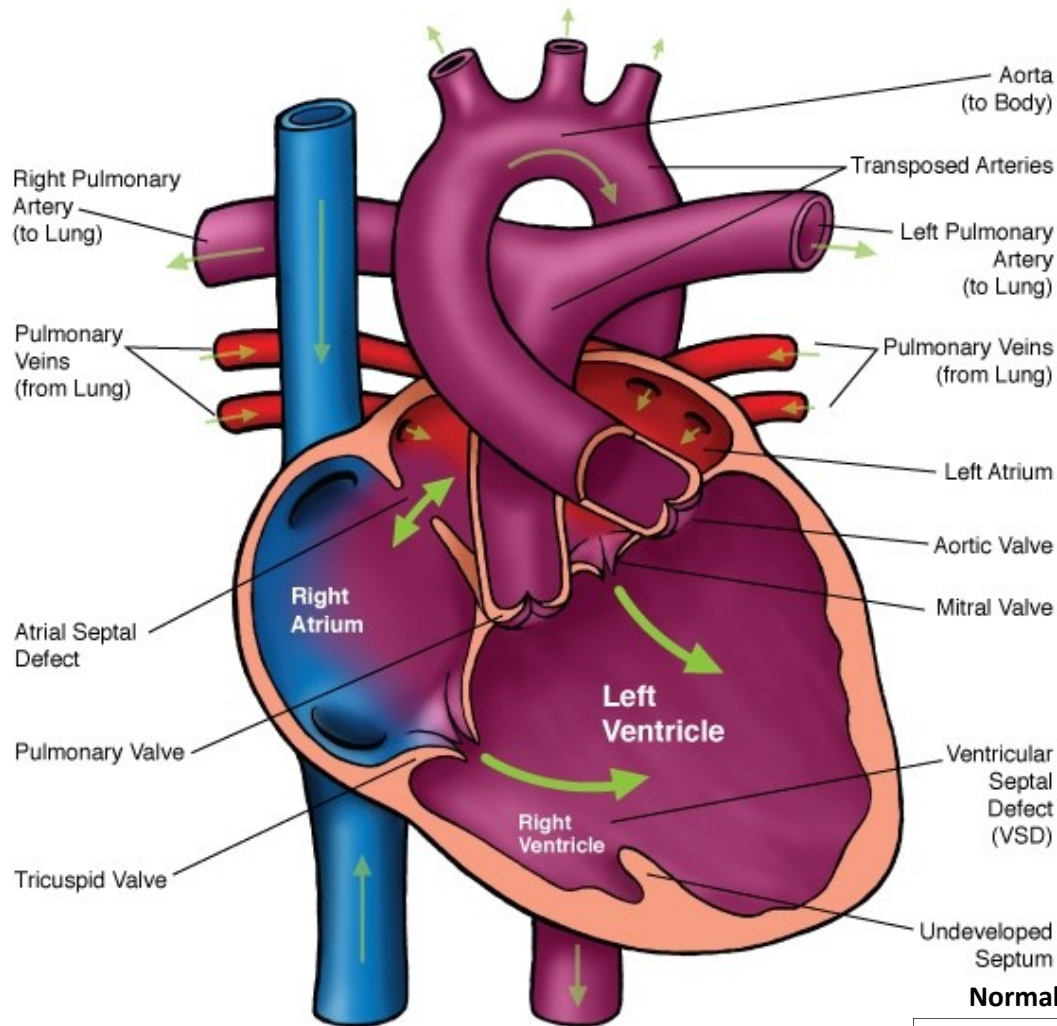
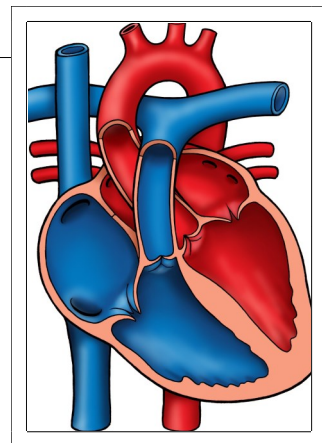




Double Inlet Left Ventricle (DILV)



Normal Heart



NOTES:

Children's Heart Clinic, P.A., 2530 Chicago Avenue S, Ste 500, Minneapolis, MN 55404
 West Metro: 612-813-8800 * East Metro: 651-220-8800 * Toll Free: 1-800-938-0301 * Fax: 612-813-8825
 Children's Hospitals and Clinics of MN, 2525 Chicago Avenue S, Minneapolis, MN 55404
 West Metro: 612-813-6000 * East Metro: 651-220-6000

Double Inlet Left Ventricle (DILV)

Double inlet left ventricle (DILV) refers to a cardiac arrangement where both atrioventricular (AV) valves are connected to a main single ventricular chamber. One or both of the AV valves may be stenotic (narrow). The main ventricular chamber is connected via the narrow bulboventricular foramen to a small, underdeveloped ventricle. Oxygenated and deoxygenated blood mix in the single ventricle. One great artery arises from the main chamber and the other arises from the underdeveloped chamber. The main chamber has the anatomic characteristics of the left ventricle in 80% of patients with double inlet ventricle. The pulmonary valve is stenotic or atretic (absent) in 50% of patients with DILV. This leads to decreased pulmonary blood flow and cyanosis (oxygen saturations less than 85%). When the pulmonary valve is normal, pulmonary blood flow is excessive and saturations are near normal. The great arteries are transposed in 85% of cases. The mitral valve is usually right sided and the tricuspid valve is on the left side. Coarctation or interrupted aortic arch is also commonly associated with DILV. DILV occurs in less than 1% of all infants with congenital heart defects.

Physical Exam/Symptoms:

With increased pulmonary blood flow:

- Infants exhibit mild cyanosis, poor feeding/weight gain, tachypnea (fast breathing), and dyspnea (labored breathing).
- A grade 3/6 systolic murmur is audible at the left sternal border. A loud S3 or an apical diastolic murmur may be heard.

With decreased pulmonary blood flow:

- Moderate to severe cyanosis is present at birth
- A grade 2-3 systolic ejection murmur is audible at the left or right upper sternal border.
- Clubbing is often present in older infants and children.

Diagnostics:

- Chest X-ray: Normal heart size and pulmonary vascularity when pulmonary blood flow is normal or decreased. The heart size is large and pulmonary vascularity is increased when pulmonary blood flow is increased.
- EKG: Abnormal Q waves are present in either the right precordial leads, both the right and left precordial leads or not present in any precordial leads. Ventricular hypertrophy with similar QRS complexes across most or all precordial leads is common.
- Echocardiogram: Diagnostic.

Medical Management/Treatment:

- For infants who are diagnosed with DILV in utero, it is recommended that delivery take place in a tertiary care hospital with transfer to Neonatal Intensive Care Unit as soon as possible to initiate cardiology evaluation and medical interventions.
- Medical therapy at birth, such as prostaglandin E infusion, is needed for newborns with severe pulmonary stenosis or atresia, coarctation, or interrupted aortic arch.
- If symptoms of congestive heart failure begin, anticongestive medications are indicated.
- Surgical palliation in multiple stages is required (see [Modified Blalock-Taussig Shunt](#), DKS, [Bidirectional Glenn Shunt](#), [Modified Fontan Procedure](#)).
- Antibiotic prophylaxis against bacterial endocarditis is recommended prior to dental procedures.
- Life-long cardiology follow up is needed.

Long-Term Outcomes:

- Without surgery for children with excessive pulmonary blood flow, 50% of children do not survive. Surviving children develop pulmonary vascular obstructive disease after one year of age.
- AV valve regurgitation is poorly tolerated and requires medication and often surgery to manage.
- Complete heart block occurs in 12% of children.
- Long-term survival and developmental outcomes vary depending AV valve competency and the presence of absence of other co-morbidities.