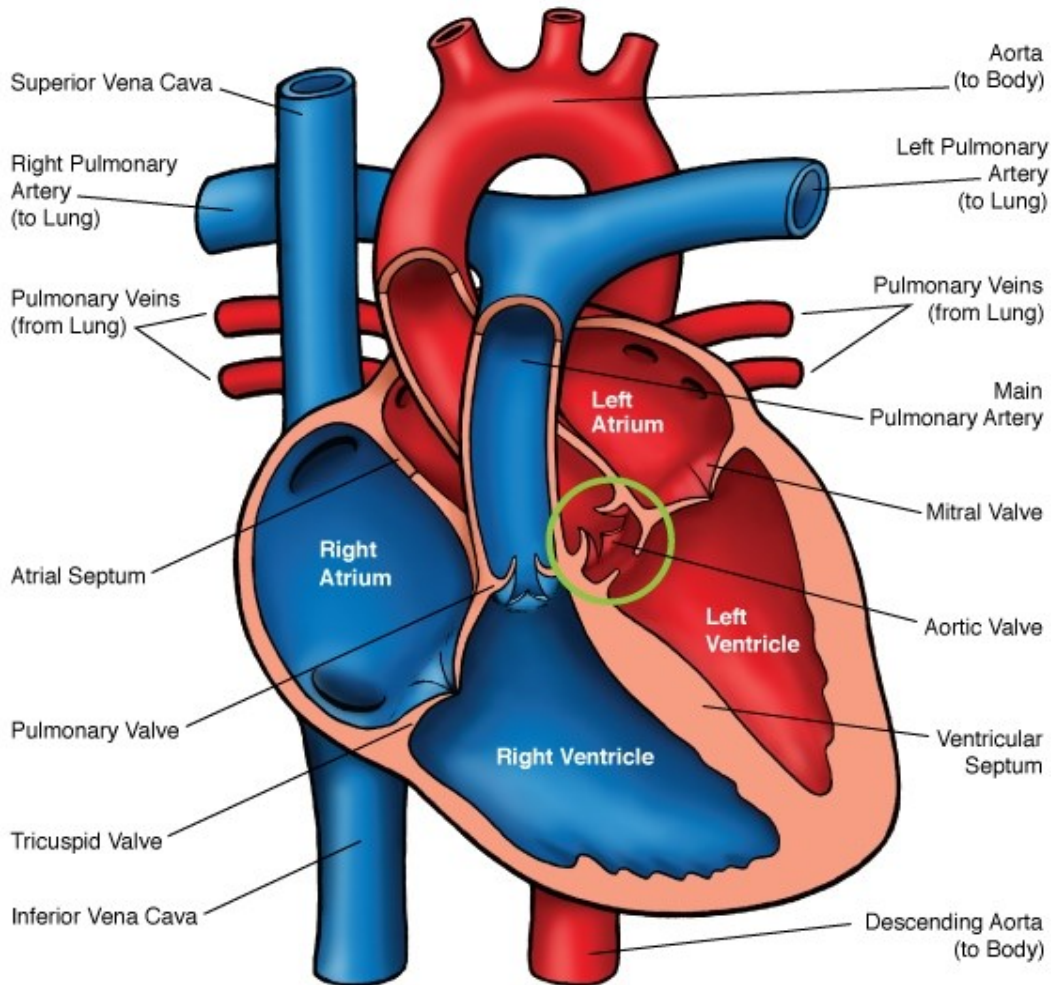
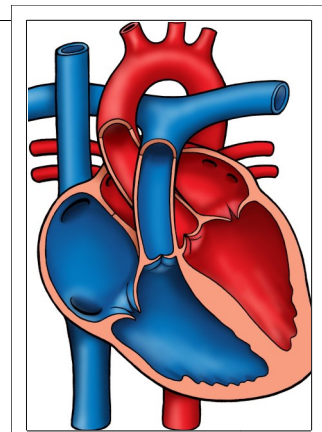




Aortic Stenosis - Subaortic



Normal Heart



NOTES:

Children's Heart Clinic, P.A., 2530 Chicago Avenue S, Ste 500, Minneapolis, MN 55404
 West Metro: 612-813-8800 * East Metro: 651-220-8800 * Toll Free: 1-800-938-0301 * Fax: 612-813-8825
 Children's Hospitals and Clinics of MN, 2525 Chicago Avenue S, Minneapolis, MN 55404
 West Metro: 612-813-6000 * East Metro: 651-220-6000

Aortic Stenosis: Subaortic (SAS)

Aortic stenosis (AS) is a narrowing or obstruction of the left ventricular outflow tract (LVOT) that occurs above, below, or at the level of the aortic valve. Subaortic stenosis (SAS) refers to severe narrowing or obstruction *below* the level of the aortic valve and can be discrete or long-segment (tunnel stenosis). AS occurs in 10% of all people with congenital heart disease, with males having a higher prevalence than females (ratio 4:1). SAS occurs in 23% of people with AS.

Types:

- **Discrete:** A membranous diaphragm forms as a result of endocardial injury, or subsequent proliferation and fibrosis due to turbulence in an abnormally shaped left ventricular outflow tract. Accounts for 10% of all aortic stenosis cases. 2/3 of these patients have associated cardiac lesions, such as ventricular septal defect (VSD), coarctation of the aorta or patent ductus arteriosus (PDA). Familial subaortic stenosis has been reported.
- **Tunnel:** Long, fibromuscular narrowing of the left ventricular outflow tract. This defect is often associated with other left ventricular anomalies (see [Shone's Syndrome](#)). Aortic valve ring, hypoplasia of the ascending aorta, and thickened aortic valve leaflets may also be present.

Physical Exam/Symptoms:

- Normal development, acyanotic (pink color)
- Normal blood pressure in mild to moderate SAS. If SAS is severe, a narrow pulse pressure will be present.
- Systolic thrill may be present at the right upper sternal border or over the carotid arteries.
- Murmur: High pitched early diastolic murmur of aortic regurgitation audible in patient with discrete subaortic stenosis.

Diagnostics:

- **Chest X-ray:** Normal heart size and pulmonary vasculature.
- **EKG:** Normal in mild cases. Left ventricular hypertrophy (enlargement) may be present in severe cases of SAS.
- **Echocardiogram:** Diagnostic

Medical Management/Treatment:

- Annual echo and cardiology visits in asymptomatic children with mild to moderate stenosis, more frequent in severe AS.
- Balloon dilation is NOT effective for subaortic stenosis.
- Surgical: In discrete subaortic SAS, the subaortic membrane is excised. When subaortic narrowing is diffuse or the annulus is hypoplastic, a procedure to widen the LVOT may be performed (see [Ross Procedure](#)).
- Life-long cardiology follow up is needed.

Long-Term Outcomes:

- Unrepaired SAS tends to worsen with time, requiring close cardiology follow up.
- 25-30% of patients may have recurrence of discrete subaortic stenosis after repair.
- Mortality rate for subaortic discrete stenosis is 0.5% and for subaortic tunnel stenosis <5%.
- Life expectancy varies depending on severity of valvar disease and other co-morbidities.
- Developmental outcomes are normal in the absence of chromosomal abnormalities or other congenital heart disease.